Current Concepts in Achilles Tendon Ruptures

Varsha Salunkhe Ivanova, DPM[a,*],
Khanh Phuong Sieu Tong, DPM, MSc[a], Cristian Neagu, DPM[b],
Christy M. King, DPM[c,d]

KEYWORDS

• Early functional rehabilitation • Minimally invasive surgery • Percutaneous surgery • Open repair

KEY POINTS

- Acute Achilles tendon ruptures can be treated either conservatively or surgically, both with functional rehabilitation and early range of motion.
- Conservative therapy has evolved from immobilization with strict non-weight-bearing protocol, to early functional rehabilitation with earlier weight-bearing.
- Surgical treatment approaches vary from percutaneous, minimally invasive, and open repair.
- Current literature discussing surgical treatment for ruptured tendons shows low incidence of complications and similar functional outcomes.

INTRODUCTION

Considered the strongest tendon in the body, the Achilles tendon (AT) has been shown to have the highest incidence of ruptures. This is attributed to an aging population, obesity, and participation in sporting activities.[1] Some studies have shown a close association between tendon degeneration, medications (ie, fluoroquinolones, local corticosteroids), and systemic disease.[2] The injury has a bimodal distribution with a peak occurring in young males (20–39 year olds) and a second peak in middle-aged patients (40–59 year olds). The tendon, often pathologic in nature, ruptures with a forced dorsiflexion moment on a plantarflexed ankle. Typically, the ruptured tendon can be diagnosed with a clinical examination and utilization of the Thompson sign.[3,4]

[a] Kaiser Permanente Foot and Ankle Surgery, 700 Lawrence Expressway, Santa Clara, CA 95051, USA; [b] Kaiser Permanente Santa Clara Foot and Ankle Surgery, 700 Lawrence Expressway, Santa Clara, CA 95051, USA; [c] Kaiser Permanente, Department of Foot & Ankle Surgery, 3600 Broadway, Clinic 17, Oakland, CA 94611, USA; [d] Kaiser San Francisco Bay Area Foot & Ankle Residency Program, Oakland, CA, USA
* Corresponding author. 700 Lawrence Expressway, Santa Clara, CA 95051.
E-mail address: varsha.ivanova@gmail.com

Clin Podiatr Med Surg 41 (2024) 153–168
https://doi.org/10.1016/j.cpm.2023.09.001
podiatric.theclinics.com
0891-8422/24/© 2023 Elsevier Inc. All rights reserved.

Downloaded for Anonymous User (n/a) at The Ohio State University from ClinicalKey.com by Elsevier on December 25, 2023. For personal use only. No other uses without permission. Copyright ©2023. Elsevier Inc. All rights reserved.

The goal of acute AT rupture treatment is to allow the tendon to heal in a shortened position to avoid overlengthening the tendon and loss of strength and propulsion. This can be accomplished either with nonsurgical or surgical intervention (minimally invasive or open repair), both with early functional rehabilitation. Either treatment option offers excellent functional outcome with overall low risks.

ETIOLOGY AND DIAGNOSIS

The most common mechanism of injury leading to an AT rupture is participation in sports or recreational activity.[5] In a retrospective study of the epidemiology of AT ruptures, Lemme and colleagues found that out of 854 AT ruptures, recreational activity or sports accounted for 81.9% of all injuries with basketball (42.6%), soccer (9.9%), and football (8.4%) being most common in males, whereas in female patients, the most common mechanism of injury was volleyball (15.2%), basketball (14.8%), followed by track and field, gymnastics, and running/hiking.[5]

AT ruptures occur with an initial propulsive force with the knee extended followed by rapid dorsiflexion or with aggressive dorsiflexion of a plantarflexed ankle. An acceleration–deceleration event has been described in a large percentage of sports injuries.[6] As many as 25% of injuries can be missed at the time of diagnosis.[6] Clinically, local swelling, bruising, a palpable gap, positive Thompson's test, and decreased ankle plantar flexion strength typically suffice for an accurate diagnosis. MRI or ultrasonography is not routinely performed to confirm the presence of an acute rupture, however, may be performed to confirm the extent or location of the rupture, evaluate gap distance, or assist in surgical planning in delayed or chronic injuries.

ANATOMY

The AT is the primary muscle that produces ankle plantar flexion and is located within the superficial posterior muscle compartment of the lower leg. It is composed of the medial and lateral heads of the gastrocnemius and soleus muscle. The larger and stronger medial head of the gastrocnemius originates from the supracondylar ridge and adductor tubercle of the popliteal surface of the femur, whereas the lateral head originates from the lateral epicondyle. Both heads share the popliteal ligament as an additional origin. The soleus muscle originates distal to the knee from the posterior proximal tibia and the proximal one-third fibula posteriorly. These muscle bellies come together to form the AT, with the soleus forming the deeper portion, approximately 5 to 6 cm proximal to the insertion at the calcaneal tuberosity. As the tendon traverses distally, the medial fibers rotate posteriorly and lateral fibers rotate laterally, with an overall 90º rotation beginning above the region where the soleus and gastrocnemius join. This places the gastrocnemius portion on the lateral and posterior aspect of the tendon.[7–9] The tendon is rounded approximately 4 cm proximal to the insertion and flattens as it expands into a cartilaginous soft tissue structure and attaches to the posterior surface of the middle one-third of the calcaneal tuberosity.

At the insertion point of the AT, the tendinous fibers insert to the calcaneus via Sharpey's fibers. The endotenon is continuous with the periosteum, and superficial fibers are continuous with the fibrous tissue of the calcaneus extending distally to join the plantar fascia.[8,10–13] **Fig. 1** details the anatomy of the AT and change in the orientation of the tendon fibers.[14]

The plantaris is present in 92% to 94% of people and is a short muscle arising from the posterior surface of the femur, just proximal to the lateral femoral condyle. It has a long tendon that traverses between the gastrocnemius and soleus muscles and

Downloaded for Anonymous User (n/a) at The Ohio State University from ClinicalKey.com by Elsevier on December 25, 2023. For personal use only. No other uses without permission. Copyright ©2023. Elsevier Inc. All rights reserved.

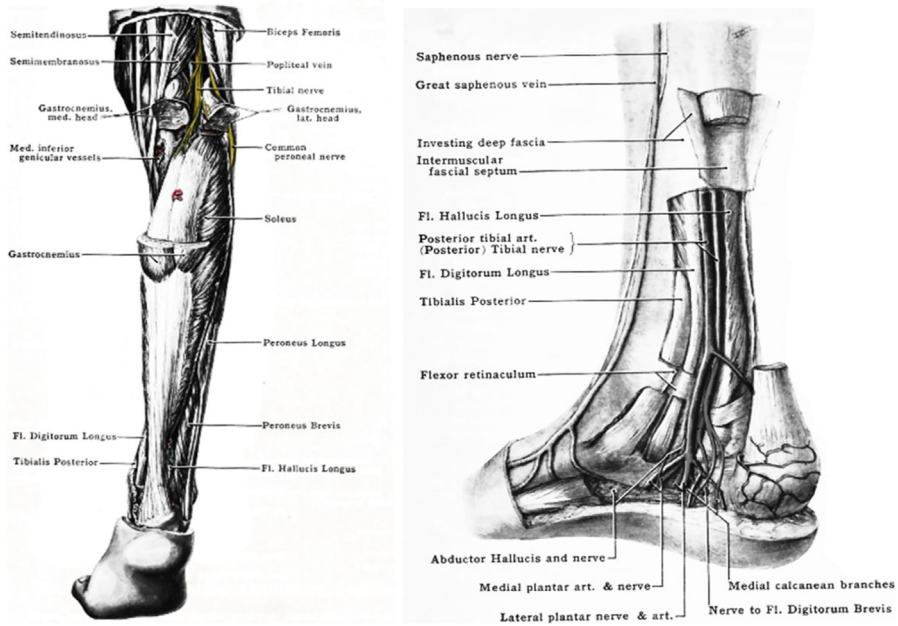

Fig. 1. Anatomy of the Achilles tendon and posterior ankle. (*From* Grant, J. C.Boileau. Grants Atlas of Anatomy. 5th ed.)

inserts into the medial border of the AT. In 6% to 8% of patients, this tendon separately inserts into the flexor retinaculum.[8]

Unlike most tendons, the AT is void of a tendinous sheath but is enclosed in a peritenon. This sheath is continuous proximally with crural fascia and distally with calcaneal periosteum. The peritenon is composed of connective tissue consisting of collagen type I, III, IV, and V, allows for gliding, and provides vascularity to the tendon.[8,15]

Considerations: Vascularity

Vascularity to the tendon is taken into account when considering the location of the rupture as well as for surgical planning. Historically, understanding of the vascular supply to the AT originated from Langergren's 1958 study, which designated the site of most frequent ruptures as a "watershed area."[16] The presence of this ischemic zone was believed to lead to tissue weakness and propensity for rupture. This theory was almost immediately challenged by Hastad who found continuous flow throughout the tendon.[17,18] A careful analysis of the AT shows that it receives its blood supply from different sources depending on anatomic location. Proximally, at the myotendinous junction, blood vessels from the surrounding tissues provide majority of vascularization, whereas the peritenon has been found to provide the circulation to the midportion of the AT. The distal one-third draws its blood supply from the blood vessels that supply the tendon–bone junction. Despite originating from three different anatomic locations, the overall blood supply to the AT is continuous in a longitudinal matter without actually penetrating the tendon fibers themselves.

A closer look by Yepes and colleagues at the skin and subcutaneous tissues of 10 cadaver legs found consistency within the blood supply to the AT.[19] They identified three vascular zones. The medial vascular zone, anatomically located between the posterior medial border of the tendon and posterior border of the medial malleolus,

Downloaded for Anonymous User (n/a) at The Ohio State University from ClinicalKey.com by Elsevier on December 25, 2023. For personal use only. No other uses without permission. Copyright ©2023. Elsevier Inc. All rights reserved.

was found to be supplied by the posterior tibial artery via three or four perforating vessels and be significantly denser than the posterior zone. The lateral vascular zone, located between the posterior lateral border of the AT and posterior border of the lateral malleolus, was noted to have its peritenon and skin circulatory status provided by the peroneal artery and in 30% of specimens by recurrent branch of the peroneal artery. Similarly, the density in this region was greater than the posterior region. Finally, the posterior vascular zone, located directly over the AT, obtains its blood supply directly from perforating arteries and arterioles originating in the subcutaneous tissue and posterior peritenon. Aside from providing a clearer look at the vascular supply to the AT, their study made recommendations for incision placement during open AT repairs: Surgeons should favor either a medial incision located at least 1 cm medial to the AT or lateral incision with an associated risk of sural nerve injury. A straight posterior incision should be avoided given significant paucity of blood vessels, which may subsequently lead to a potential increase in wound complications.

If, as described above, the vascular supply to the AT is not compromised anatomically, are there other factors leading to potential ruptures? Under normal circumstances, physical activity produces an increase in metabolic demand characterized by cardiovascular redistribution of blood flow secondary to local vasodilation, which acts as a feedforward mechanism for exercise hyperemia.[17] Previous studies have shown that normal regulation of blood flow to skeletal muscle is age-dependent and thought to be a function of vascular stiffness and poor functioning of this feed forward mechanism.[20] Wezenbeek and colleagues have confirmed what other studies have already shown, a lower increase in blood flow in the 40- to 55-year-old group versus the younger cohort post-exercise, which can lead to decreased tensile strength with potential for structural weakness and poor healing potential.[21]

Considerations: Tendon Quality

Under normal circumstances, the AT is composed of multiple parallel bundles of type I collagen. Multiple fibrils are linked in succession to achieve the length of the tendon. This arrangement requires transfer of stress among individual units. In their findings, Jacobs and colleagues performed biopsies of ruptured ATs and found diffuse fibrosis, degenerative tendinous changes, and areas of longitudinal clefts due to fiber dissociation.[22] Their findings are consistent with previously published studies that showed that preexisting symptoms and degenerative changes in the AT can contribute to partial or complete rupture in injuries. Recent studies have, however, shown that chronic tendon changes are absent in approximately 25% of Achilles ruptures.[23] Type I collagen makes up 95% of the uninjured tendon fibers, whereas an injured tendon initially heals with type III collagen in injured, leading to less resistance to tensile forces and potentially higher rates of re-rupture.[24]

Considerations: Gap Distance

Gap distance defined as the distance between the ruptured tendon ends and can be used to guide treatment decisions and outcomes. In the literature, gap distance is most commonly measured using ultrasound because it can be measured with the ankle in a fully plantarflexed position.[25] In 2020, Yassin and colleagues assessed whether the size of tendon gap measured in maximum plantar flexion affects patient-reported outcomes following AT rupture treated with functional rehabilitation.[25] With a cohort of 82 patients, they found that increasing gap size over 5 mm predicts lower patient-reported outcomes, as measured by the Achilles Tendon Rupture Score. They concluded that a tendon gap greater than 5 mm may be a useful predictor in physically demanding individuals, and a tendon gap greater than 10 mm for those

Downloaded for Anonymous User (n/a) at The Ohio State University from ClinicalKey.com by Elsevier on December 25, 2023. For personal use only. No other uses without permission. Copyright ©2023. Elsevier Inc. All rights reserved.

with low physical demand. On the other hand, Mubark and colleagues conducted a prospective case series (n = 56) with the gap distance measured with the ankle in neutral position.[26] By using AT gap measured in neutral position using ultrasound, re-rupture rates and outcome scores did not correlate with the size of the tendon gap. The results of these studies support that the ultrasound measured gap distance should be measured in maximum plantar flexion and can help influence potential outcomes and rate of re-rupture.

TREATMENT

Acute AT ruptures can be treated conservatively or with surgery. Conservative management of AT rupture has evolved from prolonged cast immobilization to utilization of early functional rehabilitation.[27] Surgical treatment has also evolved from long incisions to minimally invasive and percutaneous approaches.[28,29] The first article to compare conservative and surgical treatment was published by Jacobs and colleagues in 1978 who found superior functional outcomes in the operative group with plantar flexion force as compared with the nonoperative group; however, there was a paradigm shift with the publication of the early functional rehabilitation protocol with or without surgery by Willits and colleagues.[22,27]

Regardless of the treatment method, recent studies have shown that Soleus atrophy leading to loss of end-range plantar flexion torque is a common and persistent problem after AT ruptures, which will affect a patient's return to normal physical activity.[30] This finding was mirrored by Hodgens who found that Women's National Basketball Association (WNBA) players experience significant decrease in performance following AT rupture compared with preinjury level with 41.2% of players that return to the sport failing to play for more than one season and 23.5% of players failing to return to the sport following the injury.[31] Ultimately, the decision for conservative and surgical treatment will depend on multiple factors.

CONSERVATIVE TREATMENT

Conservative management of AT rupture previously involved prolonged cast immobilization, which is successful due to the tendon's ability to heal spontaneously in the position it is in, especially when tendon ends that are well opposed in a plantarflexed ankle are healthy and not pathologic.[32,33] However, side effects of prolonged immobilization are calf muscle atrophy and ankle joint stiffness to name a few. Deng and colleagues performed a large systematic review and meta-analysis of randomized controlled trials (RCTs) and found a re-rupture rate in the surgical group of 3.7% and nonsurgical group of 9.8%.[34] Of the nonsurgical group, approximately 30% were immobilized in a non-weight-bearing boot for 8 to 10 weeks.[34] Early weight-bearing in conjunction with functional rehabilitation has further been shown to have improved rates of re-rupture to that of prolonged non-weight-bearing of 3% and 5%, respectively.[35] Furthermore, the most of the re-ruptures have been found to take place within the first 12 weeks of surgery.[36]

Functional rehabilitation, which involves 2 to 3 weeks of cast immobilization, followed by controlled early weight-bearing, range of motion, and strengthening, helps to minimize these potential side effects. Several researchers have explored outcomes following a more functional rehabilitation protocol.[27] Willits and colleagues performed the first large RCT that compared outcomes of operative versus nonoperative treatment of acute AT ruptures.[27] Their study included 144 patients (118 males), with a mean age of 40.4 $\pm$ 8.8 years; 72 patients were treated operatively, and 72 patients were treated nonoperatively. Patients in the operative treatment group were treated in an open

Downloaded for Anonymous User (n/a) at The Ohio State University from ClinicalKey.com by Elsevier on December 25, 2023. For personal use only. No other uses without permission. Copyright ©2023. Elsevier Inc. All rights reserved.

approach with Krackow-type stitch and plantarflexed splint. Both groups were treated with an initial non-weight-bearing plantarflexed splint for 2 weeks (either from day of injury or day of surgery), then transitioned to a walking boot with a 3 cm heel lift, similar to protocol outlined in **Table 1**. Researchers followed patients for 2 years and analyzed the outcomes including: re-rupture rate, strength range of motion, calf circumference, and Leppilahti score, a disease-specific functional outcome measure.[3] There was no statistically significant difference between the two groups, suggesting conservative therapy with the additional of functional rehabilitation for acute AT ruptures is an appropriate treatment alternative to surgical repair. More recently, a large systematic study of RCTs compared the functional outcomes of early controlled motion and weight-bearing (<3 weeks of rupture) and immobilization and delayed weight-bearing; their results found no statistically significant differences between re-rupture rate, return to sport/work, and heel-rise work.[6] Almost 20 years ago, the Cochrane review published in 2004, showed the risk of re-rupture for surgical versus conservatively treated patients to be 3.5% and 12.6%, respectively.[38] However, in more recent studies, the re-rupture rate was found to be lower to around 2% to 3% with decreased period of cast immobilization and early functional rehabilitation.[27,39]

Nonoperative early functional rehabilitation treatment has been implemented in athletes and found to have a higher rate of return to pre-injury activity level in those with a lower pre-injury activity level.[40] In a study comparing pre-injury high-level activity (participation in competitive or recreational sports), and low-level activity (light/heavy labor, gymnastics, low-impact jogging/cycling), 67% of patients were able to return to their pre-injury high-level activity.[34] Functional outcomes including calf circumference, one-legged hop, and loss of power were not found to be statistically significantly different in both groups. In their findings, Deng and colleagues and Willits and colleagues found no statistically significant differences in incidence of deep vein thrombosis in surgically and conservatively treated groups.[27,34] At Kaiser Permanente Northern California, a modified early functional rehabilitation protocol was developed in conjunction with podiatry and physical therapy to optimize patient education and help to support return to activity (see **Table 1**).

SURGICAL TREATMENT

Surgical treatment for acute tendon rupture repair includes newer techniques such as percutaneous repair and minimally invasive surgery as well as the classic open repair. The goal of surgical repair is to anatomically reapproximate the ruptured tendon ends with a suture material to aid in regaining the appropriate length and tension.

PERCUTANEOUS REPAIR AND MINIMALLY INVASIVE SURGERY

Percutaneous AT repair was developed as early as 1977 by Ma and Griffith as an alternative to open procedures, which led to high risk of complications.[28] The initial percutaneous approach described involves six stab incisions (approximately 1 cm long) and was able to reduce skin incision size. However, it was initially associated with a high rate of re-rupture and nerve injury given lack of suturing under direct visualization. Utilization of the Ma and Griffith percutaneous repair led to sural nerve palsy in as many as 60% of the patients; however, later studies reported significantly lower rate of sural nerve complications at approximately 7%.[28,41] This has been primarily attributed to an increase in surgeon experience as well as development of surgical jigs, which make the surgical steps more predictable.

Modifications to the technique occurred in 1996 by Assal who developed a device that allowed visualization of the rupture site via small incisions (approximately

Downloaded for Anonymous User (n/a) at The Ohio State University from ClinicalKey.com by Elsevier on December 25, 2023. For personal use only. No other uses without permission. Copyright ©2023. Elsevier Inc. All rights reserved.

Table 1
The Kaiser Permanente Northern California modified early functional rehabilitation protocol

Phase I: Immediate Post-Injury Period (0–2 to 3 wk)	
Rehabilitation goals	Protect tendon repair Reduce swelling, minimize pain Patient education Keep your leg up and elevated when sitting or lying down Do not put weight on the injured side Do not pivot on your injured side
Weight-bearing restrictions and precautions	Weight-bearing restrictions and precautions Weight-bearing status: Cast for 2–3 wk, strict non-weight-bearing Showering: Keep the cast clean and dry. You should cover it with a secure plastic wrap, so it does not get wet. Stairs: When climbing stairs, make sure you are leading with the non-injured side. It can be a safe alternative to go up and down the stairs on your buttocks.
Intervention	Swelling management: Ice, compression, elevation Cardio: upper body ergometer
Criteria to progress	2–3 wk
Phase II: Intermediate Post-Injury Period (2 to 3–6 wk)	
Rehabilitation goals	Continue to protect the tendon repair while allowing for early range of motion to decrease adhesions
Weight-bearing restrictions	Weight-bearing status: Protected weight-bearing in the walking boot with $\sim 3 \times 5/16$ heel lifts with crutch assistance. Heel lift height may vary per person. Sleeping: Keep the boot on at night when sleeping Showering: Use shower chair Stairs: When climbing or going downstairs, make sure you are leading with the uninjured side
Additional interventions	Swelling control: Ice, compression, elevation Cardio: upper body ergometer Scar management (if surgically corrected) Massage incision site You can apply topical scar treatments like vitamin E oil, Mederma cream (available in pharmacies), or silicon impregnated bandages (ie, Scar away or Mepiform available online) Range of motion/mobility Active range of motion plantar flexion, inversion, eversion, dorsiflexion from maximum plantar flexion to neutral (do not dorsiflex past neutral) Strengthening Hip and knee strengthening 3-way hip Short/long arc quads Prone hamstring curls Open chain core
Criteria to progress	6 wk No wound complications Dorsiflexion to neutral

(*continued on next page*)

Downloaded for Anonymous User (n/a) at The Ohio State University from ClinicalKey.com by Elsevier on December 25, 2023. For personal use only. No other uses without permission. Copyright ©2023. Elsevier Inc. All rights reserved.

Table 1
(*continued*)

Phase III: Late Post-Injury Period (6–8 wk)	
Rehabilitation goals	Start progression of weight-bearing without the boot increase dorsiflexion range of motion Safely progress strengthening Promote proper movement patterns Avoid post-exercise pain and swelling Avoid activities that produce pain at injured site
Weight-bearing restrictions	Weight-bearing status: Protected weight-bearing in the walking boot Week 6: Remove first heel lift Week 7: Remove second and third heel lifts Week 8: Start walking without the boot in supportive shoe Sleeping: You no longer need to sleep with the boot on
Additional interventions (continue with phase II interventions)	Cardio: Bike, swimming, water aerobics Scar management: Cross-friction massage incision site as needed Range of motion and mobility Gentle calf stretching, non-weight-bearing Ankle mobilizations, as needed Strengthening Ankle dorsiflexion, plantar flexion, inversion, eversion with resistance band Progress to weight-bearing hip/knee strengthening by week 8 Bridges, squats, step ups Neurologic re-education/proprioception Static balance progression
Criteria to progress	Decrease in swelling and pain after exercise Dorsiflexion active range of motion to at least 5 Single leg stance for 30 s
Phase IV: Transitional Post-Injury Period (9–12 wk)	
Rehabilitation goals	Achieve full dorsiflexion range of motion Safely progress calf strengthening Promote proper movement patterns Avoid post-exercise pain and swelling
Additional interventions (continue with phase II–III interventions as needed)	Cardio: Bike, swimming, water aerobics, elliptical machine Range of motion and mobility Calf stretching in weight-bearing Ankle mobilizations, as needed Strengthening Initiate heel raise progression, concentric and eccentric Functional movements Squats à single leg squat Lunges (forward, lateral, reverse) Step ups, step downs Neurologic re-education and proprioception Dynamic balance progression
Criteria to progress/return to impact training	Dorsiflexion range of motion equal to the contralateral side Ten repetitions of straight leg (SL) heel raise through 85% range of motion (contralateral side)

(*continued on next page*)

Downloaded for Anonymous User (n/a) at The Ohio State University from ClinicalKey.com by Elsevier on December 25, 2023. For personal use only. No other uses without permission. Copyright ©2023. Elsevier Inc. All rights reserved.

Table 1
(*continued*)

Phase V: Early Return to Sport Period (3–5 mo)	
Rehabilitation goals	Maintain full range of motion Initiate plyometric program Safely initiate sport specific training program Avoid post-exercise pain and swelling
Additional interventions (continue with phase II–IV interventions)	Cardio: Bike, swimming, elliptical, running Plyometrics Partial body weight with shuttle press 1. Bilateral hops 2. Alternating hops 3. Single leg hops Frontal plane on land 4. Bilateral side to side 5. Single leg side to side 6. Skaters Sagittal plane on land 7. Bilateral hops in place, forward/backward 8. Single leg hops in place, forward backward 9. Box jumps
Criteria to progress/return to run criteria	Single leg standing heel raise test: 90% Limb Symmetry Index (10 incline1 rep:2 s rate for 60 s, no. of reps performed) Single leg hop for distance 90% Limb Symmetry Index Single leg squat 45, 10 reps with good form
Phase VI: Unrestricted Return to Sport Period (6 mo)	
Rehabilitation goals	Safely return to sport
Additional interventions (continue with phase II–V interventions as needed)	Sport-specific agility and plyometric training Examples: Lateral shuffle, grapevine Backwards running Shuttle run Sport cord drills Ladder drills T-agility Box drill Zig-zag run Cutting and pivoting
Criteria to progress/return to unrestricted sport	Drop countermovement jump Limb Symmetry Index 90% (vertical drop from standard stair height of 20 cm) Ability to complete one repetition declined heel raise set at 20°

Courtesy of Christy King, DPM and Kaillin Collins, DPT, Kaiser Permanente, Oakland, CA.[37]

5 cm long) and more precise suturing techniques led to a reduced risk for wound complications and rates of infection.[42] This is known as a mini open repair. Gatz and colleagues performed a multi-study analysis including 25 level I–III studies that only reported quantitative data under the outcomes of interest.[29] In their study, they found that compared with open repair, the minimally invasive surgical group had a shorter surgical duration, a lower rate of postoperative wound necrosis (0.38% vs 2.23% with open repair), superficial infection (0.19% vs 2.55% with open repair), and deep infection (2.20% vs 5.11% with open repair) and also experienced less scar tissue

Downloaded for Anonymous User (n/a) at The Ohio State University from ClinicalKey.com by Elsevier on December 25, 2023. For personal use only. No other uses without permission. Copyright ©2023. Elsevier Inc. All rights reserved.

with lesions (0.86% vs 4.57% with open repair). Similarly, no statistically significant differences were noted among the open and minimally invasive surgical approach with regard to postoperative re-rupture rates (2.10% vs 2.38% with open repair). Overall, compared with an open approach, visualization is limited with a percutaneous and minimally invasive approach, leading to higher risk of sural nerve injury; however, wound healing complications and re-rupture rates are comparable in more recent research.[43]

OPEN REPAIR

Open AT repair is used less than before with the advent of both early functional rehabilitation as well as percutaneous or minimally invasive approaches. Potential risks reported with the open approach include surgical site infection, wound dehiscence, and sural nerve injury. Although older studies reported higher rates of infection, wound dehiscence, and sural nerve injury, more recent studies have shown the risks to be significantly lower, allowing surgeons to reconsider the open approach.[44] Yamaguchi reported that despite an unchanged incidence of AT ruptures in Japan, 70% of patients underwent open surgical repair of their ruptures from 2010 to 2017.[44]

Multiple RCTs compare surgical and nonsurgical treatment options with recommendations dependent on chronicity of the studies. Pre-2005 RCTs reported a higher re-rupture rate with the conservative group, but despite higher rates of skin and neural entrapment complications recommended surgical repair.[45,46] Later studies showed that incorporation of early range of motion and weight-bearing led to similar re-rupture rates, calf circumference, functional outcomes, and strength.[47] In a recent retrospective study evaluating tendon length after operative or nonoperative treatment of AT ruptures, no statistically significant difference was found at a 1-year follow-up.[48] **Fig. 2**A shows a minimally plantarflexed ankle at rest and a palpable dell in the case of an AT rupture. **Fig. 2**B shows the results of open repair of the AT with the foot in more plantarflexed position at rest.

Historically, the Bunnell suture was reported to be superior, whereas the Krackow was associated with a higher potential of damage to the tendon secondary to increased strangulation and potential reduction of vascular supply.[49,50] It was also shown to be more technically difficult on the surgeon. Recent studies assessed the biomechanics of the sutures and found the double Bunnell to be the most resistant and also have the lowest degree of tendon elongation at the level of the rupture. Similar results with regard to resistance were noted in the Kraków suture; however, it resulted in greater elongation of the tendon.[51] **Figs. 3** and **4** show the frayed tendon ends of an acute AT rupture open repair and reapproximation of the tendon ends with

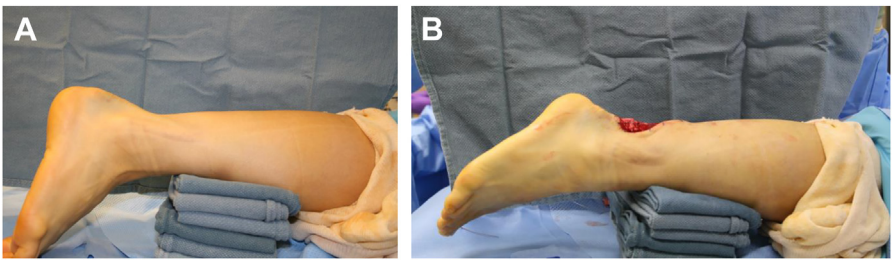

Fig. 2. (*A*, *B*) Acute ruptured Achilles tendon is notable for a posterior dell and dorsiflexed ankle joint at rest. Post-tendon open tendon rupture repair shows a plantarflexed ankle at rest.

Downloaded for Anonymous User (n/a) at The Ohio State University from ClinicalKey.com by Elsevier on December 25, 2023. For personal use only. No other uses without permission. Copyright ©2023. Elsevier Inc. All rights reserved.

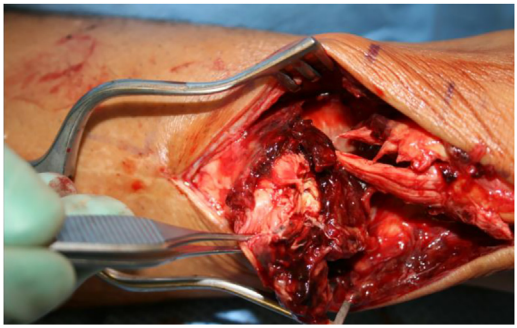

Fig. 3. Frayed tendon ends of an acute Achilles tendon rupture.

nonabsorbable suture in a Krakow fashion. Despite the close opposition of tendon ends, the weakest point of the surgical repair rests with the surgical knots. Specialized suturing techniques were developed by Bunnell, Kessler, and Krackow with good results (**Fig. 5**).[49,50,52,53]

Soroceanu and colleagues performed a meta-analysis of 10 RCTs and compared an operatively treated group (either open or minimally invasive techniques) and nonoperatively treated group (with or without functional rehabilitation with early range of motion).[36] Their data demonstrated similar rates of re-rupture with operative and nonoperative with functional rehabilitation (risk difference 1.7%, $P = .45$). Furthermore, there was no statistically significant difference between the nonoperative and operative groups regarding calf circumference, strength, and functional outcome. Patients treated operatively are found to return to work sooner than those treated conservatively.[47]

CHRONIC RUPTURE TREATMENT

Although the best treatment approach to acute Achilles ruptures is debatable, it is well accepted in the literature that open repair of AT injuries is indicated in the setting of chronic ruptures as well as acute injuries in the young, healthy, athletic patient. In most cases, however, the choice of surgical procedure is surgeon and patient-dependent. The goal of management of a chronic Achilles rupture is to bring the injured tendon ends in close apposition, restore normal length–tension to improve

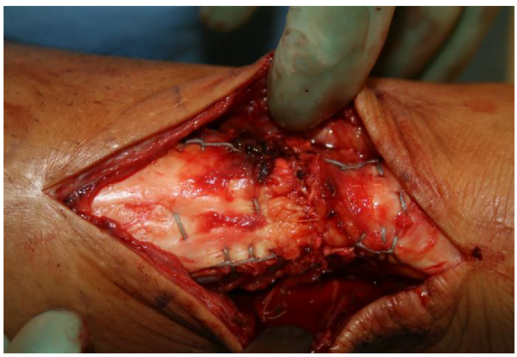

Fig. 4. Ruptured tendon reapproximated with nonabsorbable suture in Krakow fashion.

Downloaded for Anonymous User (n/a) at The Ohio State University from ClinicalKey.com by Elsevier on December 25, 2023. For personal use only. No other uses without permission. Copyright ©2023. Elsevier Inc. All rights reserved.

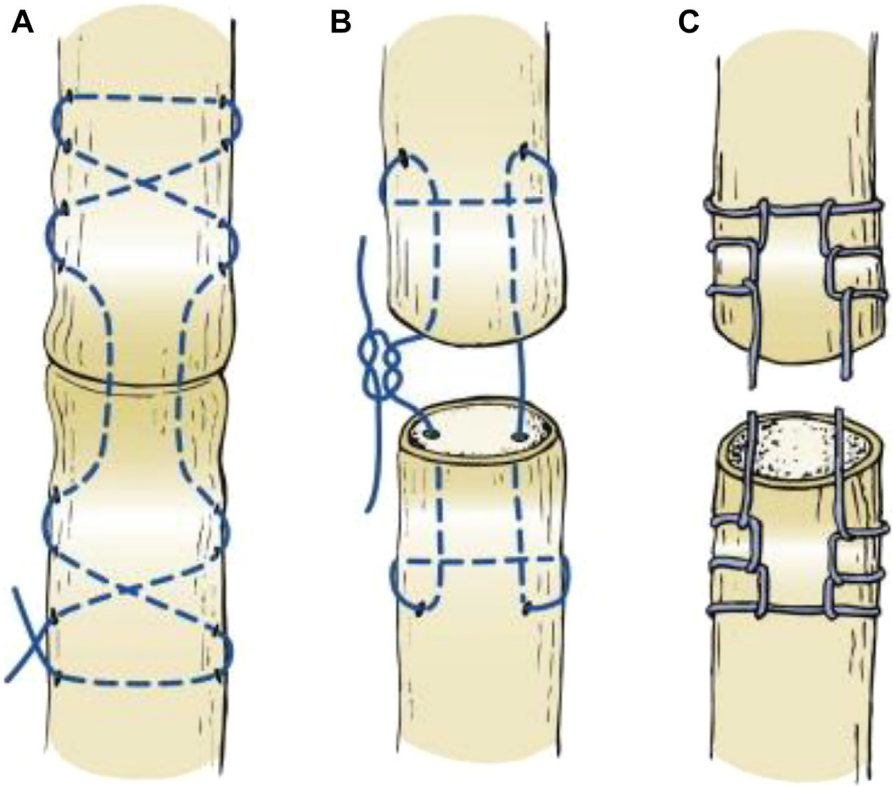

Fig. 5. Tendon repair techniques. (*A*) Modified Bunnell technique. (*B*) Kessler technique. (*C*) Krackow technique. (*From* Coughlin MJ Saltzman CL Anderson RB. Mann's Surgery of the Foot and Ankle. Ninth ed. Philadelphia PA: Saunders/Elsevier; 2014.)

strength with an early return to normal function while maintaining complications to a minimum.

The open surgical repair technique for chronic ruptures depends on several factors, including age of the AT injury, time from injury to surgery, size of the defect, and intraoperative findings.[54] In most cases, if the defect between measures less than 3 cm, an end-to-end repair can be performed using a multi-strand, long chain ultra-high molecular weight braided polyethylene suture.[55] Defects larger than 3 cm may require a gastrocnemius recession or myotendinous flaps to increase the length of the muscle and close the rupture gap. Techniques using flexor hallucis longus or plantaris tendon have been described to augment the repair and improve local blood supply without functional deficiencies distally at the digital level.[55,56]

Open repair of the AT continues to remain a good option in the setting of an acute rupture and the recommended form of treatment for chronic ruptures. Historically, studies have shown a lower rate of re rupture as compared with the conservatively managed patients, which was offset with employment of functional rehabilitation programs aimed at early range of motion and weight-bearing. Surgeons must however take into consideration the possible complications commonly associated with surgery such as superficial and deep infection occurring in 2.6% and 5.1% of patients, respectively.[29] Surgically treated patients have been shown to have an early return to weight-bearing and return to work.

Downloaded for Anonymous User (n/a) at The Ohio State University from ClinicalKey.com by Elsevier on December 25, 2023. For personal use only. No other uses without permission. Copyright ©2023. Elsevier Inc. All rights reserved.

SUMMARY

There is an ongoing debate between the risks and benefits of conservative and operative treatment of AT ruptures. Regardless of treatment selected, research supports the importance of functional rehabilitation with weight-bearing whether with or without surgery. Several comparative studies have been published that review the risks, benefits, and functional outcomes of operatively and nonoperatively treated AT ruptures.[29] The main complications compared include rates of re-rupture, infection, and functional outcomes. Functional outcomes after an AT rupture may be poor due to the risk of tendon elongation, inevitable muscle weakness, and decreased push off strength. Complications in the open repair such as superficial and deep infections, sural nerve injury, and re-rupture are significantly improved with new percutaneous repair techniques. Overall, recent literature shows a similar rate of re-rupture between the surgical and nonsurgical treatment groups if a functional rehabilitation protocol with early range of motion and weight bearing is performed.

CLINICS CARE POINTS

- Early diagnosis and treatment of Achilles tendon ruptures are imperative to avoid complications of chronic Achilles tendon ruptures.
- Recent literature shows similar rates of re-rupture with conservative or surgical treatment.
- Weight-bearing functional rehabilitation plays an important role in the recovery after Achilles tendon injuries, treated with or without surgery.

DISCLOSURES

The authors have nothing to disclose regarding conflict of interest or commercial relationship related to the content of this work.

REFERENCES

1. Raikin SM, Garras DN, Krapchev PV. Achilles tendon injuries in a United States population. Foot Ankle Int 2013;34(4):475–80.
2. Järvinen TAH, Kannus P, Maffulli N, et al. Achilles tendon disorders: etiology and epidemiology. Foot Ankle Clin 2005;10(2):255–66.
3. Leppilahti J, Orava S. Total Achilles tendon rupture. A review. Sports Med 1998; 25(2):79–100.
4. Maffulli N. Current concepts in the management of subcutaneous tears of the Achilles tendon. Bull Hosp Jt Dis 1998;57(3):152–8.
5. Lemme NJ, Li NY, DeFroda SF, et al. Epidemiology of Achilles tendon ruptures in the United States: athletic and nonathletic injuries from 2012 to 2016. Orthop J Sports Med 2018;6(11). 2325967118808238.
6. Gobbi A, Espregueira-Mendes J, Lane JG, et al. Bio-orthopaedics: a new approach. Berlin, Germany: Springer; 2017.
7. Barfred T. Experimental rupture of the Achilles tendon. Comparison of various types of experimental rupture in rats. Acta Orthop Scand 1971;42(6):528–43.
8. O'Brien M. The anatomy of the Achilles tendon. Foot Ankle Clin 2005;10(2): 225–38.
9. Benjamin M, Evans EJ, Copp L. The histology of tendon attachments to bone in man. J Anat 1986;149:89–100.

Downloaded for Anonymous User (n/a) at The Ohio State University from ClinicalKey.com by Elsevier on December 25, 2023. For personal use only. No other uses without permission. Copyright ©2023. Elsevier Inc. All rights reserved.

10. Kvist M. Achilles tendon overuse injuries: a clinical and pathophysiological study in athletes with special reference to Achilles Paratenonitis. 1991.
11. Allenmark C. Partial Achilles tendon tears. Clin Sports Med 1992;11(4):759–69.
12. Kvist M. Achilles tendon injuries in athletes. Sports Med 1994;18(3):173–201.
13. Jones FW. Structure and Function as Seen in the Foot.; 1949.
14. Boileau GJC. Grant's atlas of anatomy. Baltimore, MD: Williams & Wilkins; 1972. p. 318–21.
15. Schepsis AA, Jones H, Haas AL. Achilles tendon disorders in athletes. Am J Sports Med 2002;30(2):287–305.
16. Lagergren C, Lindbom A, Soderberg G. Hypervascularization in chronic inflammation demonstrated by angiography; angiographic, histopathologic, and microangiographic studies. Acta Radiol 1958;49(6):441.
17. Fadel PJ. Reflex control of the circulation during exercise. Scand J Med Sci Sports 2015;25(suppl 4):74–82.
18. Hastad K, Larsson LG, Lindholm A. Clearance of radiosodium after local deposit in the Achilles tendon. Acta Chir Scand 1959;116:251–5.
19. Yepes H, Tang M, Geddes C, et al. Digital vascular mapping of the integument about the Achilles tendon. J Bone Joint Surg Am 2010;92(5):1215–20.
20. CMJr Hearon, Dinenno FA. Regulation of skeletal muscle blood flow during exercise in ageing humans. J Physiol 2016;594(8):2261–73.
21. Wezenbeek E, Willems T, Mahieu N, et al. The role of the vascular and structural response to activity in the development of achilles tendinopathy: a prospective study. Am J Sports Med 2018;46(4):947–54.
22. Jacobs D, Martens M, Van Audekercke R, et al. Comparison of conservative and operative treatment of Achilles tendon rupture. Am J Sports Med 1978;6(3):107–11.
23. Park YH, Kim TJ, Choi GW, et al. Achilles tendinosis does not always precede Achilles tendon rupture. Knee Surg Sports Traumatol Arthrosc 2019;27(10):3297–303.
24. Tarantino D, Palermi S, Sirico F, et al. Achilles tendon rupture: mechanisms of injury, principles of rehabilitation and return to play. J Funct Morphol Kinesiol 2020;5(4). https://doi.org/10.3390/jfmk5040095.
25. Yassin M, Myatt R, Thomas W, et al. Does size of tendon gap affect patient-reported outcome following Achilles tendon rupture treated with functional rehabilitation? Bone Joint Lett J 2020;102-B(11):1535–41.
26. Mubark I, Abouelela A, Arya S, et al. Achilles tendon rupture: can the tendon gap on ultrasound scan predict the outcome of functional rehabilitation program? Cureus 2020;12(9):e10298.
27. Willits K, Amendola A, Bryant D, et al. Operative versus nonoperative treatment of acute Achilles tendon ruptures: a multicenter randomized trial using accelerated functional rehabilitation. J Bone Joint Surg Am 2010;92(17):2767–75.
28. Ma GW, Griffith TG. Percutaneous repair of acute closed ruptured achilles tendon: a new technique. Clin Orthop Relat Res 1977;128:247–55.
29. Gatz M, Driessen A, Eschweiler J, et al. Open versus minimally-invasive surgery for Achilles tendon rupture: a meta-analysis study. Arch Orthop Trauma Surg 2021;141(3):383–401.
30. Wenning M, Mauch M, Heitner A, et al. Midterm functional performance following open surgical repair of acute Achilles tendon rupture. Arch Orthop Trauma Surg 2022;142:1337–49.

Downloaded for Anonymous User (n/a) at The Ohio State University from ClinicalKey.com by Elsevier on December 25, 2023. For personal use only. No other uses without permission. Copyright ©2023. Elsevier Inc. All rights reserved.

31. Hodgens B, Geller J, Rizzo MG, et al. Performance outcomes after surgical repair of achilles tendon rupture in the women's national basketball association. Orthopaedic Journal of Sports Medicine 2021;9(9). 23259671211030473.
32. Bruns J, Kampen J, Kahrs J, et al. Achilles tendon rupture: experimental results on spontaneous repair in a sheep-model. Knee Surg Sports Traumatol Arthrosc 2000;8(6):364–9.
33. Lea RB, Smith L. Rupture of the achilles tendon. Nonsurgical treatment. Clin Orthop Relat Res 1968;60:115–8.
34. Deng S, Sun Z, Zhang C, et al. Surgical treatment versus conservative management for acute achilles tendon rupture: a systematic review and meta-analysis of randomized controlled trials. J Foot Ankle Surg 2017;56(6):1236–43.
35. Young SW, Patel A, Zhu M, et al. Weight-bearing in the nonoperative treatment of acute achilles tendon ruptures: a randomized controlled trial. J Bone Joint Surg Am 2014;96(13):1073–9.
36. Reito A, Logren HL, Ahonen K, et al. Risk factors for failed nonoperative treatment and rerupture in acute achilles tendon rupture. Foot Ankle Int 2018;39(6):694–703.
37. King CM, Vartivarian M. Achilles tendon rupture repair: simple to complex. Clin Podiatr Med Surg 2023;40(1):75–96.
38. Khan RJ, Carey Smith RL. Surgical interventions for treating acute Achilles tendon ruptures. Cochrane Database Syst Rev 2010;9:CD003674.
39. Nilsson-Helander K, Silbernagel KG, Thomeé R, et al. Acute achilles tendon rupture: a randomized, controlled study comparing surgical and nonsurgical treatments using validated outcome measures. Am J Sports Med 2010;38(11):2186–93.
40. Lerch TD, Schwinghammer A, Schmaranzer F, et al. Return to sport and patient satisfaction at 5-year follow-up after nonoperative treatment for acute achilles tendon rupture. Foot Ankle Int 2020;41(7):784–92.
41. Grassi A, Amendola A, Samuelsson K, et al. Minimally invasive versus open repair for acute achilles tendon rupture: meta-analysis showing reduced complications, with similar outcomes, after minimally invasive surgery. J Bone Joint Surg Am 2018;100(22):1969–81.
42. Assal M, Jung M, Stern R, et al. Limited open repair of Achilles tendon ruptures: a technique with a new instrument and findings of a prospective multicenter study. J Bone Joint Surg Am 2002;84(2):161–70.
43. Li Y, Jiang Q, Chen H, et al. Comparison of mini-open repair system and percutaneous repair for acute Achilles tendon rupture. BMC Musculoskelet Disord 2021;22(1):914.
44. Yamaguchi S, Kimura S, Akagi R, et al. Increase in achilles tendon rupture surgery in Japan. Orthopaedic Journal of Sports Medicine 2021;9(10).
45. Moller M, Movin T, Granhed H, et al. Acute rupture of tendon Achillis: a prospective randomised study of comparison between surgical and nonsurgical treatment. J Bone Joint Surg Br 2001;83:84.
46. Bhandari M, Guyatt G, Siddiqui F, et al. Treatment of acute Achilles tendon ruptures: a systematic overview and metaanalysis. Clin Orthop Relat Res 2002;400:190–200.
47. Soroceanu A, Sidhwa F, Aarabi S, et al. Surgical versus nonsurgical treatment of acute Achilles tendon rupture: a meta-analysis of randomized trials. J Bone Joint Surg Am 2012;94(23):2136–43.
48. Cramer A, Rahdi E, Hansen MS, et al. No clinically relevant difference between operative and non-operative treatment in tendon elongation measured with the

Downloaded for Anonymous User (n/a) at The Ohio State University from ClinicalKey.com by Elsevier on December 25, 2023. For personal use only. No other uses without permission. Copyright ©2023. Elsevier Inc. All rights reserved.

Achilles tendon resting angle (ATRA) 1 year after acute Achilles tendon rupture. Knee Surg Sports Traumatol Arthrosc 2021;29(5):1617–26.
49. Krackow KA, Thomas SC, Jones LC. A new stitch for ligament-tendon fixation. Brief note. J Bone Joint Surg Am 1986;68(5):764–6.
50. Bunnell S, Boyes JH. Bunnell's surgery of the hand. Philadelphia, PA: J.P. Lippincott; 1970.
51. Manent A, Lopez L, Vilanova J, et al. Assessment of the resistance of several suture techniques in human cadaver achilles tendons. J Foot Ankle Surg 2017;56:954–9.
52. Kessler I, Nissim F. Primary repair without immobilization of flexor tendon division within the digital sheath. An experimental and clinical study. Acta Orthop Scand 1969;40(5):587–601.
53. Coughlin MJ, Saltzman CL, Anderson RB. Mann's surgery of the foot and ankle. 9th edition. Philadelphia PA: Saunders/Elsevier; 2014.
54. Kuwada GT. An update on repair of achilles tendon rupture. acute and delayed. J Am Podiatr Med Assoc 1999;89(6):302–6.
55. Aktas S, Kocaoglu B, Nalbantoglu U, et al. End-to-end versus augmented repair in the treatment of acute Achilles tendon ruptures. J Foot Ankle Surg 2007;46(5):336–40.
56. Maffulli N, Gougoulias N, Christidis P, et al. Primary augmentation of percutaneous repair with flexor hallucis longus tendon for Achilles tendon ruptures reduces tendon elongation and may improve functional outcome. Knee Surg Sports Traumatol Arthrosc 2023;31(1):94–101.

Downloaded for Anonymous User (n/a) at The Ohio State University from ClinicalKey.com by Elsevier on December 25, 2023. For personal use only. No other uses without permission. Copyright ©2023. Elsevier Inc. All rights reserved.